

Worksheet

Integumentary System

True or False

Examine the following statements. Identify if the statement is true or false

True False

1. The dermis is the outermost portion of the skin.
2. Sebaceous glands secrete sweat.
3. Cicatrization is scar formation.
4. Keratin is found in subcutaneous tissue.
5. The medical term for baldness is alopecia.
6. Squamous cell and basal cell carcinomas involve epithelial tissue.
7. Shingles is caused by a fungal infection.
8. Inflammation of the fingernail is called onychia.
9. Cutaneous tissue is found in the integumentary system.
10. A symptom of scleroderma is thinning of the skin.

Fill-in-the-Blank

Complete the sentence with the correct term(s).

Answers

11. The uppermost portion of the skin is the _____.
12. The layer of tissue beneath the skin is described as _____.
13. The oily secretion that lubricates the skin is _____.
14. The main pigment in skin is _____.
15. The protein that makes up hair and nails is _____.
16. The study of the skin and skin diseases is _____.
17. A tumor of melanocytes is called _____.
18. Alopecia is a loss of _____.
19. A fungal infection of the hair is termed _____.
20. Itchiness can be relieved by using a(n) _____ agent.
21. The medical term for a mole or birthmark is _____.
22. The medical term for a wart is _____.
23. Sweat is produced by a(n) _____ gland.
24. Skin, hair, and nails make up the _____ system.
25. The root onych/o means _____.
26. An agent that prevents or relieves itching is a(n) _____.
27. A gland that produces sebum is the _____.
28. The skin and its associated glands, hair, and nails make up the _____ system.
29. The layer of tissue beneath the skin is the _____ tissue.
30. _____ means producing or secreting sweat or pertaining to a sweat gland.
31. The term _____ refers to study of the skin and diseases of the skin.

32. The process of scar formation is known as _____ (hint: a scar is a cicatrix).

33. A chronic hereditary dermatitis with red lesions covered by silvery scales is known as _____.

34. Profuse sweating is called _____.

35. The skin gland that vents directly to the surface of the body is the _____.

Matching

Match the following terms and write the appropriate letter next to each term.

Term	Answers	Definition
36. hypohidrosis		A. fungal infection of a hair
keratosis		B. horny growth of skin
trichomycosis		C. inflammation around a nail
paronychia		D. deficiency of sweat production
37. stratum corneum		A. material that drains from a wound
pyoderma		B. uppermost layer of the epidermis
exudate		C. disruption of a wound
dehiscence		D. presence of pus in the skin
38. escharotomy		A. hardening of the skin
scleroderma		B. removal of a scab
psoriasis		C. a fluid-filled blister
vesicle		D. skin disease with redness and silvery scales
39. urticaria		A. excess flow of sebum
macule		B. hives
diaphoresis		C. profuse sweating
seborrhea		D. a flat colored spot

Pronounce It

For each phonetic transcription in this section, pronounce the term aloud and write it in the space provided, being careful to spell it correctly.

	Answers		Answers
40. wele		50. KER-ah-tin	
41. es-kar-OT-o-me		51. SE-bum	
42. e-vis-er-A-shun		52. sik-ah-trih-ZA-shun	
43. KE-loyd		53. de-HIS-ens	
44. PEM-fih-gus		54. EK-ze-mah	
45. pru-RI-tus		55. se-BA-shus	
46. so-RI-ah-sis		56. sub-ku-TA-ne-us	
47. al-o-PE-she-ah		57. su-dor-IF-er-us	
48. eks-AN-them		58. in-teg-u-MEN-tah-re	
49. ku-TA-ne-us			

Word Building

For each item in this section, select the correct word parts from the bank below to form the term that matches the definition. Word parts may be used more than once.

Part 1**Answers**

60. Congenital disorder of dry scaly skin

61. Loosening or separation of the skin

62. Instrument for cutting skin

63. Inflammation of a sweat gland

64. Resembling skin

65. Softening of a nail

66. Like or resembling a hair

67. Production of foul-smelling sweat

68. Any disease of the skin

69. Absence of sweating

Part 1 Word Bank

a	an	derm
ichthy	lysis	o
onych	sis	trich
aden	brom	hydr
itis	malacia	oid
path	tome	y

Sorting

For each word part category in this section, list the corresponding word parts from the bank below.

Part 1 Word Bank

dermis	pemphigus	gland	gland
macule	psoriasis	stratum	vesicle
melanoma	scleroderma	basale	wheel
papule	sebaceous	sudoriferous	

Part 1

Answers

70. parts of the skin

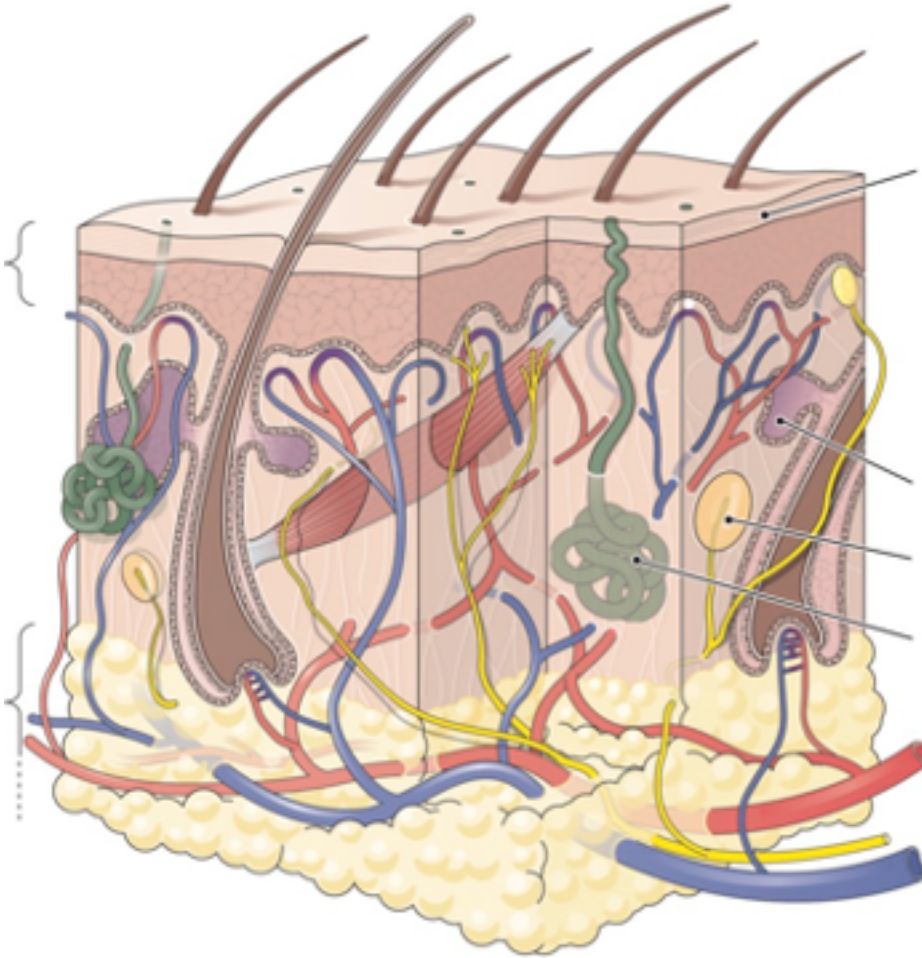
71. skin lesions

72. skin disorders

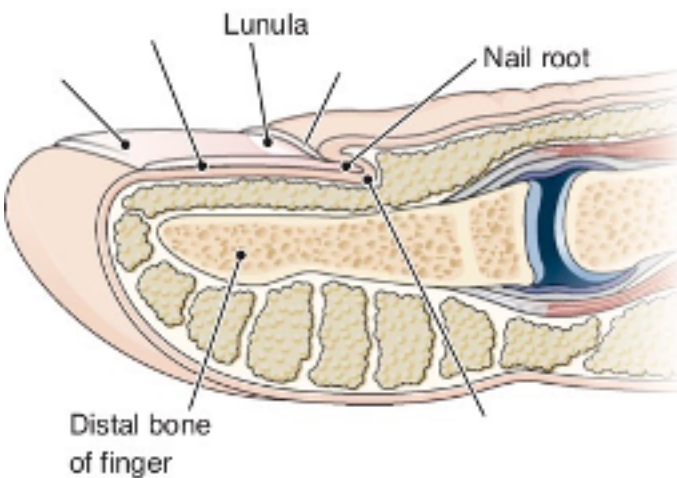
Look and Label

For each image in this section, write each label indicated on the image in the correct location or near the image with a line pointing from the label to the correct location on the image.

73. Labels: epidermis, pressure receptor, sebaceous gland, stratum corneum, subcutaneous layer, sweat gland

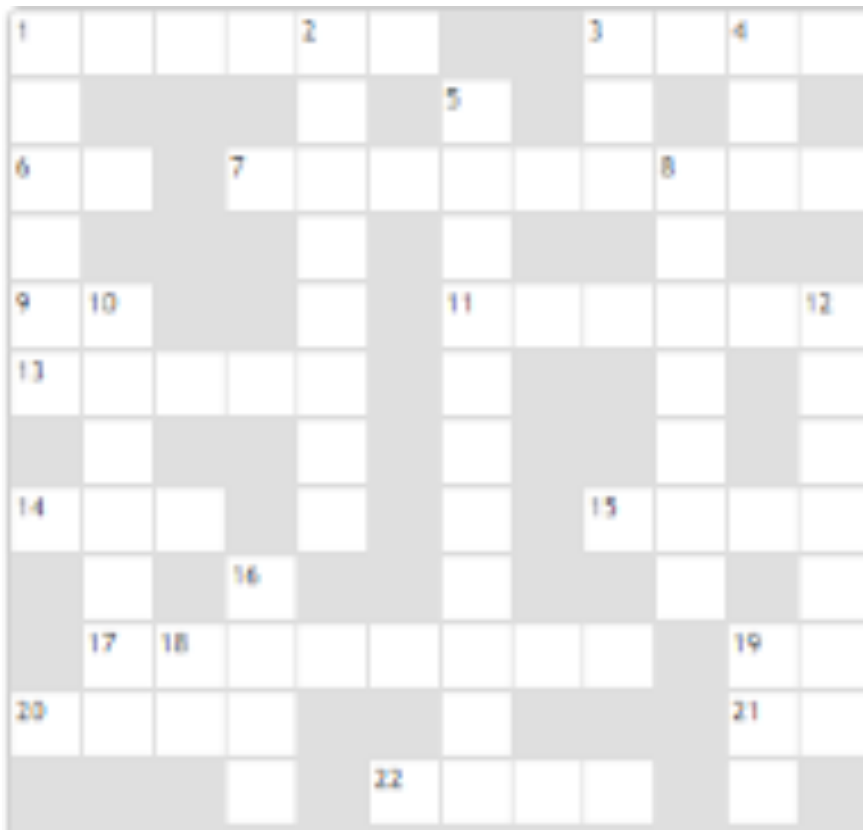

74. Labels: cuticle, growth region, nail bed, nail plate



Crossword Puzzle

75.



Across

1. Horny layer of the skin: combining form
3. Inflammation of a sweat gland: _____ adenitis
6. Autoimmune disease that affects the skin: abbreviation
7. Excess growth of hair
9. Within the skin: abbreviation
11. Viral disease that affects the skin
13. Skin: combining form
14. Three: prefix
15. Scar: _____ trix
17. Examination by pressing a glass plate against the skin
19. True, good, easy: prefix
20. Half: prefix starting with s
21. Part of a medical history: _____ H abbreviation
22. Under, below, decreased: prefix

Down

1. Raised, thickened scar
2. Pertaining to a hair
3. Measurement of packed red cells: abbreviation
4. Abnormal, painful: prefix
5. Removal of scab tissue
8. Bacterial skin infection common in children: _____ o
10. Remove dead tissue, as from a wound
12. A layer, as of the skin
16. Meaning of the root onych/o
18. A route of injection: abbreviation
19. On, over: prefix

Case Study

Read the following case studies carefully. Complete the sentence with the correct term(s).

Consultation: Seborrheic Keratosis

HISTORY OF PRESENT ILLNESS: The patient is a 58-year-old male who comes in complaining of a mole localized on the right side of the parietal area of his head. He has had this problem for at least 1 year. He is concerned that this skin lesion is getting bigger over the past several months. Otherwise, he is asymptomatic.

PAST MEDICAL HISTORY: He has chronic posterior nasal drainage that causes chronic cough, mainly at nighttime. He also has chronic nasal congestion. He denies previous history of asthma. The patient denies any previous history of skin cancer.

PAST SURGICAL HISTORY: The patient is status post bilateral carpal tunnel operations on both hands.

ALLERGIES: The patient refers that he is allergic to penicillin and allergic to Bactrim. He states that whenever he takes these medications, he has an erythematous rash as well as hives.

SOCIAL HISTORY: The patient does not smoke cigarettes. He drinks approximately one to two 12-ounce beers per day. He does not do any regular exercise. He works as a bird biologist.

FAMILY HISTORY: Unremarkable. **REVIEW OF SYSTEMS:** Unremarkable.

PHYSICAL EXAMINATION: Vital signs: Temperature 97.6, heart rate 80, respiratory rate 20, blood pressure 120/70. Weight 196 pounds. General description: Middle-aged male with no respiratory distress. HEENT exam is unremarkable. Neck exam is unremarkable. Lungs clear to auscultation. Cardiovascular exam: S1, S2, regular rhythm. No S3, no S4, no murmurs.

Abdomen: Unremarkable. Extremities: No edema. Peripheral pulses are symmetric. Neurologic: The patient is alert and oriented to place, time, and person. There are no focal sensory motor deficits. Examination of the skin reveals a 0.5-cm papule localized on the right parietal area of the scalp. This lesion is round in shape with well-defined borders. Examination of the back reveals a 1-cm papule with well-defined borders localized in the left upper back with mild hyperpigmentation. There are two similar lesions surrounding the first lesion in the left upper back with similar characteristics. The patient has several hyperpigmented lesions in the upper back that are symmetric and with well-defined borders. These lesions are mainly macules, although there are some papules with well-defined borders.

ASSESSMENT AND PLAN

- Seborrheic keratosis. The patient was reassured regarding the benign nature of these skin lesions. There is no evidence of malignancy at the moment. The patient's wife was also taught about the characteristics of seborrheic keratosis. The patient will perform a monthly skin lesion exam to rule out the possibility of skin cancer and melanoma. The patient's wife will perform the same evaluation of the skin on patient's back.
- Health maintenance. This will be addressed by this patient's primary care physician in his home state. The patient refers that he lives here just for a few months in a year. He will soon move home again.

Answers

76. Carpal tunnel operations involve the _____.

77. "Lungs clear to auscultation" means that _____ were heard with a stethoscope.

78. S1 and S2 refer to _____.